

# A three-dimensional atlas of child's cardiac anatomy and the unique morphological alterations associated with obesity

Maciej Marciniak <sup>1†</sup>, Arend W. van Deutekom <sup>2,3,4†</sup>, Liza Toemen <sup>2,3,5</sup>, Adam J. Lewandowski <sup>4</sup>, Romy Gaillard <sup>2,3</sup>, Alistair A. Young<sup>1</sup>, Vincent W.V. Jaddoe<sup>2,3,5</sup>, and Pablo Lamata <sup>1\*</sup>

<sup>1</sup>Department of Biomedical Engineering, School of Biomedical Engineering and Imaging Sciences, Kings' College London, 5th Floor Becket House, Lambeth Palace Road, London SE1 7EU, UK; <sup>2</sup>Department of Paediatrics, Erasmus MC, University Medical Center, Rotterdam, the Netherlands; <sup>3</sup>Department of Paediatrics, Generation R Study Group, Erasmus MC, University Medical Center, Wytemaweg 80, 3015 CN Rotterdam, the Netherlands; <sup>4</sup>Division of Cardiovascular Medicine, Radcliffe Department of Medicine, Oxford Cardiovascular Clinical Research Facility, University of Oxford, Level 1 Oxford Heart Centre, John Radcliffe Hospital, Headley Way, Headington, Oxford, OX3 9DU, UK; and <sup>5</sup>Department of Epidemiology, Erasmus MC, University Medical Center, Dr. Molewaterplein 40, 3015 GD Rotterdam, the Netherlands

Received 20 July 2021; editorial decision 5 December 2021; accepted 6 December 2021

## Aims

Statistical shape models (SSMs) of cardiac anatomy provide a new approach for analysis of cardiac anatomy. In adults, specific cardiac morphologies associate with cardiovascular risk factors and early disease stages. However, the relationships between morphology and risk factors in children remain unknown. We propose an SSM of the paediatric left ventricle to describe its morphological variability, examine its relationship with biometric parameters and identify adverse anatomical remodelling associated with obesity.

## Methods and results

This cohort includes 2631 children (age  $10.2 \pm 0.6$  years), mostly Western European (68.3%) with a balanced sex distribution (51.3% girls) from Generation R study. Cardiac magnetic resonance short-axis cine scans were segmented. Three-dimensional left ventricular (LV) meshes are automatically fitted to the segmentations to reconstruct the anatomies. We analyse the relationships between the LV anatomical features and participants' body surface area (BSA), age, and sex, and search for features uniquely related to obesity based on body mass index (BMI). In the SSM, 19 modes described over 90% of the population's LV shape variability. Main modes of variation were related to cardiac size, sphericity, and apical tilting. BSA, age, and sex were mostly correlated with modes describing LV size and sphericity. The modes correlated uniquely with BMI suggested that obese children present with septo-lateral tilting ( $R^2 = 4.0\%$ ), compression in the antero-posterior direction ( $R^2 = 3.3\%$ ), and decreased eccentricity ( $R^2 = 2.0\%$ ).

## Conclusions

We describe the variability of the paediatric heart morphology and identify anatomical features related to childhood obesity that could aid in risk stratification. Web service is released to provide access to the new shape parameters.

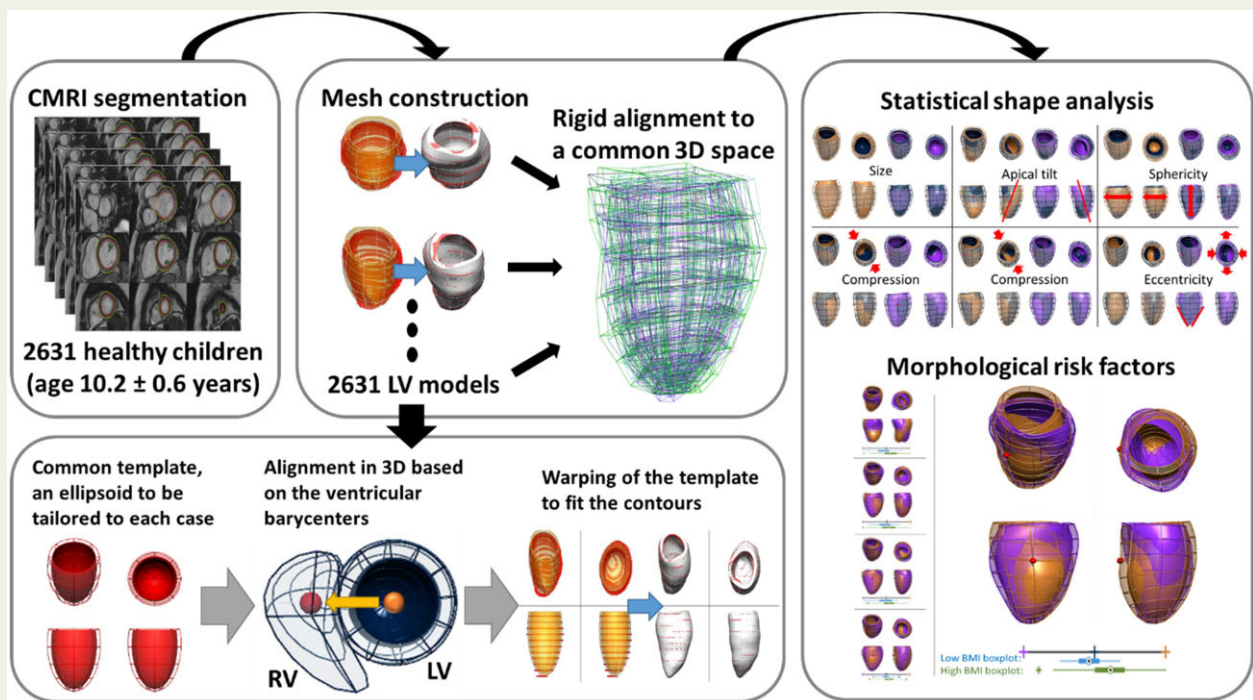
\* Corresponding author. Tel: +44 20 784 89563. E-mail: [pablo.lamata@kcl.ac.uk](mailto:pablo.lamata@kcl.ac.uk)

<sup>†</sup>The first two authors are joint first authorship.

© The Author(s) 2021. Published by Oxford University Press on behalf of the European Society of Cardiology.

This is an Open Access article distributed under the terms of the Creative Commons Attribution License (<https://creativecommons.org/licenses/by/4.0/>), which permits unrestricted reuse, distribution, and reproduction in any medium, provided the original work is properly cited.

## Graphical Abstract



## Keywords

paediatrics • obesity • risk factors • magnetic resonance imaging • epidemiology

## Introduction

Obesity remains one of the most important issues in global health. Almost 60% of EU adults and roughly one-third of 11-year-olds are overweight or obese and obesity-related conditions are the leading causes of preventable death.<sup>1,2</sup> The increased cardiovascular disease (CVD) risk associated with obesity is not only driven by hypertension, diabetes, obstructive sleep apnoea, and coronary artery disease but also by structural and functional cardiac changes.<sup>3</sup>

Three-dimensional (3D) statistical shape models (SSMs) of cardiac anatomy using cardiovascular magnetic resonance (CMR) images offer a new approach for accurate quantitative assessment of cardiac geometry, suitable for large cohort studies.<sup>4</sup> For example, SSM have been used to unveil changes in left ventricular (LV) geometry in healthy adults who were born prematurely,<sup>5</sup> to quantify remodelling patterns after myocardial infarction,<sup>6</sup> to predict response after cardiac resynchronization therapy,<sup>7</sup> and to detect early signs of heart failure in congenital heart disease.<sup>8</sup>

The application of SSM in large cohorts found that obese adults have a distinct cardiac shape that may better explain the interaction between body composition and cardiac health. In the UK Digital

Heart Project obesity was associated with asymmetric concentric hypertrophy, with women demonstrating greater cavity dilatation than men.<sup>9</sup> In the UK Biobank study, shape variants characterized by septal displacement and apical bulging had robust and strong relationships with obesity.<sup>10</sup> In both cohorts, these new measures of cardiac shape were more sensitive to detect cardiac differences associated with body mass index (BMI) than traditional measures such as LV mass (LVM) and LV end-diastolic volume (LVEDV) and were independently associated with risk factors for later CVD.

Part of the adult CVD risk associated with obesity may already develop in childhood. The Bogalusa Heart Study revealed that childhood obesity is associated with adult LV dilatation and hypertrophy and concluded that childhood BMI was the *only* independent predictor of LV hypertrophy in adulthood.<sup>11</sup> Epidemiological studies in children indicate that LV hypertrophy develops in response to obesity in childhood,<sup>12,13</sup> and relates to an increase in myocardial triglyceride content in adolescence.<sup>14</sup>

In this study, we describe the construction of an SSM from >2600 children of the Generation R study to provide a reference standard of the paediatric LV shape. We define how different 3D shape features relate to conventional geometric measurements and biometric

parameters. We hypothesize that the shape analysis can reveal an anatomical LV remodelling pattern that is uniquely associated with paediatric obesity. This knowledge may have implications for screening, prevention, and understanding the increased cardiovascular risk in obesity.

## Methods

This study draws from the Generation R study, a population-based prospective cohort study from foetal life onwards in the Netherlands.<sup>15</sup> Extensive data collection has been conducted over the years, from the early prenatal phase through childhood, to examine the development of the cardiovascular system and early cardiovascular risk factors.<sup>15,16</sup> Data collection in parents and their children included questionnaires, physical and ultrasound examinations, and CMR imaging scans. Of the initial cohort of 9749 live births, 3719 children participated in the CMR studies around the age of 10 years [min = 8.55, max = 11.99, median = 9.95, interquartile range (9.77, 10.35)]. Children's height and weight was measured (see [Supplementary data online](#)) to derive body surface area (BSA), using the Haycock formula,<sup>17</sup> sex- and age-specific BMI Z-scores (based on national reference diagrams<sup>18</sup>), and weight status (based on the definition of the International Obesity Task Force<sup>19</sup>).

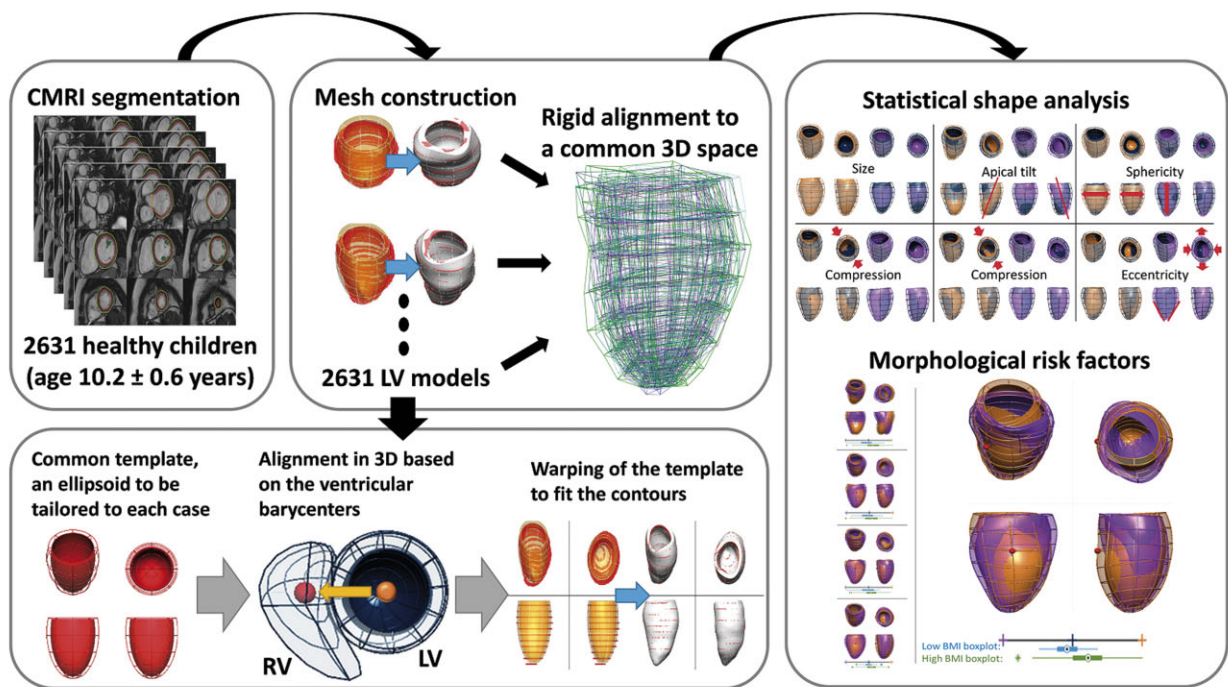
For CMR imaging, we used a standardized protocol (see [Supplementary data online](#)) to obtain a short-axis steady state free precession cine stack covering the ventricles with 8-mm thick slices. LV endo- and epicardial

borders were semi-automatically contoured using QMASS software (Medis, Leiden, the Netherlands). Traditional cardiac outcome parameters included LVEDV and LVM, based on the Simpson's method.

## Computational models

The LV 3D anatomy of each subject was reconstructed from the contours of the left ventricle at end-diastole in the short-axis stack. An anatomical personalization method that uses smooth meshes was used due to its robustness to segmentation variability.<sup>20,21</sup> In short, this method customizes an idealized LV template to the contours using image registration and mesh warping techniques and achieves sub-voxel accuracy. Anatomical correspondence across meshes was achieved by the consistent alignment between template and patient-specific contours at the initial step of the personalization process. This alignment was based on the direction perpendicular to the CMR short-axis basal plane and on the direction joining the centre of mass of the right ventricular and LV blood pools (see [Figure 1](#)).

Geometric measurements were performed on the generated meshes. LVEDV and LVM were computed from meshes by numerical integration and using the myocardial density of 1.055 g/mL.<sup>22</sup> LV mass to volume ratio (MVR) was computed from these two (LVM/LVEDV). LV length was computed from the centre of the basal plane to the furthest apical epicardial point. LV diameter was calculated as the average of the diameters of circles inscribed into the epicardial cross-section at 40–50% of the LV length, measured from the base. LV sphericity was calculated as a ratio of the LV diameter and LV

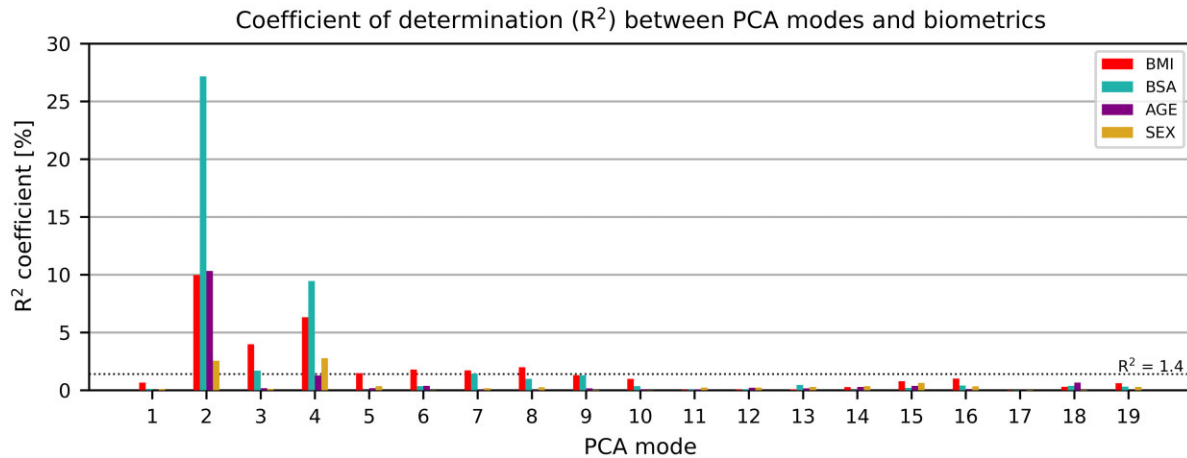


**Figure 1** Building a statistical shape model for morphological variability description and risk factors detection. Cardiac magnetic resonance short-axis cine scans from 2631 children (age 10.2 ± 0.6 years, 51% girls) were segmented. 3D LV meshes were automatically fitted to the segmentations to reconstruct the LV anatomies and registered to ensure the anatomical correspondence of each mesh. Then, a statistical shape model was computed to derive modes of shape variation. Nineteen modes described over 90% of the LV shape variability within the population. Body surface area, age, and sex were mostly correlated with modes describing LV size and sphericity. Few modes were correlated uniquely with body mass index, suggesting that obese children present with septo-lateral tilting ( $R^2 = 4.0\%$ ), compression in the antero-posterior direction ( $R^2 = 3.3\%$ ), and decreased eccentricity ( $R^2 = 2.0\%$ ).









**Figure 4** Correlation between the PCA modes and biometric parameters. Modes depicting length, sphericity, and wall thickness were highly correlated with body mass index (BMI), body surface area (BSA), and age. Modes 3, 5, 6, and 8 were mainly correlated with BMI, which signals that they may represent the morphological remodelling related to obesity. PCA, principal component analysis.

[ $R^2$  of 4.0%, 1.5%, 1.8%, and 2.0% respectively, with 95% confidence intervals of (2.6%, 5.6%), (0.7%, 2.5%), (0.9%, 2.9%), and (1.1%, 3.2%) respectively].

The optimal linear combination of modes 3, 5, 6, and 8 that discriminated (linear discriminant analysis  $P < 0.001$ , receiver operating characteristic area under the curve: 0.71) between the 214 control cases ( $BMI = 17.5 \pm 0.3 \text{ kg/m}^2$ ) and the 185 overweight or obese cases ( $BMI > 22.8 \text{ kg/m}^2$ ) in our cohort revealed the unique signature of obesity in the child's heart as shown in Figure 5: with increasing BMI, the left ventricle had an increased end-diastolic volume especially in the apical and mid segments, as well as increased anteroseptal convexity. Moreover, in obese children, the basal cross-section became more circular, compared to the elliptical shape associated with lower BMI, while also compressing the left ventricle in the antero-posterior direction. The significance levels and power analysis of these results are depicted in Supplementary data online, Table S5. This signature of obesity did not have a linear relationship with BMI across the spectrum, but became apparent from a BMI of  $19 \text{ kg/m}^2$  onwards, see panel B in Figure 5.

## Discussion

This is the first study to characterize the paediatric heart in 3D, based on a comprehensive set of CMR scans of 2631 children. It may serve as a reference standard for future cohort studies or individual patient data. Moreover, we revealed that obesity in children is associated with unique morphological signatures, characterized by an increased apical and midventricular volume, anteroseptal convexity, anteroposterior compression, and rounding of the basal and mid segments. A web service hosted at the Cardiac Atlas Project (<http://www.cardiacatlas.org>, 12 December 2021, date last accessed) is released to enable an easy access to the novel morphological descriptors.

## Morphological variability of the paediatric LV

There is considerable data on the association of sex, growth, and body size with LVM and dimensions. Cross-sectional studies of healthy children, adolescents, and young adults found that measures of body size and adiposity are the strongest correlates, reflecting greater resting LV stroke volume and output.<sup>24–27</sup> A paediatric statistical shape study could further assess and detect different phenotypes with potential prognostic information. Multiple statistical shape studies have been performed on large adult cohorts,<sup>10,28</sup> yet the developmental path of the heart shape remains understudied. The provided description of paediatric LV shape variability fills one of the knowledge gaps on cardiac growth and development.<sup>8</sup> This SSM has a potential to significantly aid the detection of individual and group changes in the healthy developmental patterns while considering various biometric parameters.

The 3D LV meshes were generated with sub-voxel accuracy and showed a good agreement in the metrics resulting from the contours. The mean difference between contour-derived and mesh-derived metrics was lower than the inter-observer variation between two experienced reviewers in a multicentre paediatric CMR study.<sup>29</sup> Small discrepancies were caused by the impact of breath-hold artefacts on the 3D meshes, differences in how to account for incomplete basal slices, and numerical differences between using the summation of disks and integration.

Variation in size, sphericity, and orientation of the LV were the main features captured by the first four modes of the paediatric LV, similarly to those observed in the adult populations.<sup>10,28</sup> The associations of shape with age and BSA suggested that as a child gets older, the heart mainly increases in size and length, more than it increases in sphericity and wall thickness. Conversely, sex was equally correlated to changes in size and sphericity, with girls having smaller, more spherical hearts than boys, in-line with the adult population studies.<sup>28</sup>



decreased eccentricity of the LV cross-section and the LV apex tilted towards the right ventricle. The results suggest that it is the mid and apical region of the heart that starts the progression towards adverse trait of sphericity, together with a decrease of eccentricity. Moreover, the 'obese cardiac phenotype' found in the paediatric LV had strong similarities with the cardiac remodelling patterns found in the presence of high afterload, i.e. aortic stenosis where LV shape was characterized by increased LV apical tilting towards the right ventricle,<sup>35</sup> as captured in mode 3 in our study.

The rate of increase in regional stress relative to pressure is greatest in the septum,<sup>36</sup> and our results reveal that adaptation to changes in BMI and BSA in modes 2 and 4 are localized to septal thickening (see [Supplementary data online, Table S6](#) and [Figure S4](#)) that agree with this mechanistic hypothesis. All thickening patterns observed in the modes correlated with change in LVM showed a relatively similar spatial distribution that concentrates in the septal wall, with a helical pattern that was described as characteristic in hypertrophic cardiomyopathy.<sup>37</sup> Concentric adaptations to altered loading conditions may preferentially develop in an asymmetric, regional pattern.<sup>36</sup> In our study, these reveal as asymmetric anatomical remodelling responses in terms of curvatures and volume distributions (see [Figure 5](#)). These changes may be explained by the pericardial loading conditions, with impact on end-diastolic morphology due to changes in thoracic pressures.

In contrast to adult studies,<sup>9</sup> cardiac shape associations with obesity were similar for boys and girls. The identified shape features related to obesity in this study may explain how childhood obesity progresses to adult CVD. For example, modes 5, 6, and 8 described different manifestations of more circular cross-section along the left ventricle in subjects with higher BMI (see [Supplementary data online, Figure S5](#)). This observation mimics findings in adults, where subjects with higher peripheral (but not abdominal) fat mass had eccentric LV remodelling and a higher cardiac output.<sup>38</sup> This indicates a heart adaptation to increased BMI by increasing both roundness of the shape and septal wall thickness to cope with higher work demand. Complex cardiac remodelling patterns may result in obesity from different stimuli, including haemodynamic loading conditions, obesity-associated pro-inflammatory factors, glucotoxicity, lipotoxicity, and leptin-resistance.<sup>39</sup> The unique shape associated with obesity may serve as a biomarker that could identify those at highest risk for later CVD, including obesity-associated heart failure (the 'obesity cardiomyopathy'). It also shows that remodelling associated with increased BMI can be regional and asymmetric.

## Limitations

The spatial orientation of the CMR short-axis slices stack may introduce image acquisition and 3D mesh variability as it is defined by the basal plane of the heart. In our study, modes 1 and 3 were mostly affected by this limitation, as they related to LV orientation in two perpendicular axes. Nevertheless, discrepancies in choice of the basal plane were random and could therefore be treated as noise—a noise shown to not affect LVEDV and ejection fraction.<sup>40</sup> Due to the exquisite detail captured by an SSM, other subtle differences in methodological steps, such as CMR acquisition parameters and segmentation style, can also have an impact in the generality of results, and as such they should be the scope of future studies.<sup>41</sup> Additionally, we chose the  $R^2_{\text{BMI}} = 1.4$  as a threshold to describe

shape modes with the highest independent correlation to BMI. Other modes with lower signatures (including modes 10, 15, and 16) could be explored in future work, as they showed significance to increase in BMI ( $P < 0.001$ ).

## Conclusions

We have described the variability in 3D shape of the paediatric heart, and identified unique anatomical features related to childhood obesity that could aid in risk stratification. A web service is released to provide easy access to the new shape parameters.

## Supplementary data

[Supplementary data](#) are available at *European Heart Journal - Cardiovascular Imaging* online.

## Acknowledgements

The authors thank Claudia Kruihof, data manager of the Generation R Study, for her invaluable help in the selection, cleaning, and transfer of data. The authors also thank Prof. Dr. Willem A. Helbing for his critical appraisal of the manuscript.

## Funding

This research was supported by the European Union's Horizon 2020 research and innovation programme under Maria Skłodowska-Curie grant agreement no. 764738 (PIC), and grant agreement no. 733206 (LifeCycle), and by the National Institute for Health Research (NIHR) Cardiovascular MedTech Co-operative. A.W.v.D. is funded by a ZonMW Rubicon grant (452183001) and a Netherlands Heart Institute Fellowship. A.J.L. is funded by a British Heart Foundation Intermediate Research Fellowship (FS/18/3/33292). R.G. received funding from the Dutch Heart Foundation (2017T013), the Dutch Diabetes Foundation (2017.81.002), and the Netherlands Organization for Health Research and Development (NWO, ZonMW, 543003109). V.W.V.J. was supported by a European Research Council Consolidator Grant (ERC-2014-CoG-648916). P.L. holds a Wellcome Trust Senior Research Fellowship (209450/Z/17/Z). The Generation R Study is made possible by financial support from the Erasmus Medical Centre, Rotterdam, and the Erasmus University Rotterdam.

**Conflict of interest:** none declared.

## Data availability statement

The data underlying this article are partially available in Cardiac Atlas Project, at <https://www.cardiacatlas.org/>. The data include the 3D average mesh, and the meshes representing the shape modes. The meshes built from the CMR images cannot be shared publicly for the privacy of the individuals participating in the study. No new CMR images were generated in support of this research.

## References

1. WHO/Europe | Obesity—Data and Statistics. <https://www.euro.who.int/en/health-topics/noncommunicable-diseases/obesity/data-and-statistics> (10 July 2021, date last accessed).
2. OECD iLibrary | *The Heavy Burden of Obesity: The Economics of Prevention*. [https://www.oecd-ilibrary.org/social-issues-migration-health/the-heavy-burden-of-obesity\\_67450d67-en](https://www.oecd-ilibrary.org/social-issues-migration-health/the-heavy-burden-of-obesity_67450d67-en) (10 July 2021, date last accessed).
3. Wong C, Marwick TH. Obesity cardiomyopathy: pathogenesis and pathophysiology. *Nat Clin Pract Cardiovasc Med* 2007;**4**:436–43.



4. Young AA, Frangi AF. Computational cardiac atlases: from patient to population and back. *Exp Physiol* 2009;**94**:578–96.
5. Lewandowski AJ, Augustine D, Lamata P, Davis EF, Lazdam M, Francis J et al. Preterm heart in adult life: cardiovascular magnetic resonance reveals distinct differences in left ventricular mass, geometry, and function. *Circulation* 2013;**127**:197–206.
6. Lekadir K, Albà X, Pereañez M, Frangi AF. Statistical shape modeling using partial least squares: application to the assessment of myocardial infarction. In: Camara A, Mansi T, Pop M, Rhode K, Sermesant M, Young A (eds). *Lecture Notes in Computer Science (Including Subseries Lecture Notes in Artificial Intelligence and Lecture Notes in Bioinformatics)*. Cham, Switzerland: Springer Verlag; 2016. p130–9.
7. Warriner DR, Jackson T, Zacur E, Sammut E, Sheridan P, Hose DR et al. An asymmetric wall-thickening pattern predicts response to cardiac resynchronization therapy. *JACC Cardiovasc Imaging* 2018;**11**:1545–6.
8. Gilbert K, Forsch N, Hegde S, Mauger C, Omens JH, Perry JC et al. Atlas-based computational analysis of heart shape and function in congenital heart disease. *J Cardiovasc Transl Res* 2018;**11**:123–32.
9. Corden B, de Marvao A, Dawes TJ, Shi W, Rueckert D, Cook SA et al. Relationship between body composition and left ventricular geometry using three dimensional cardiovascular magnetic resonance. *J Cardiovasc Magn Reson* 2016;**18**:1–8.
10. Gilbert K, Bai W, Mauger C, Medrano-Gracia P, Suinesiaputra A, Lee AM et al. Independent left ventricular morphometric atlases show consistent relationships with cardiovascular risk factors: a UK Biobank Study. *Sci Rep* 2019;**9**:1–9.
11. Berenson GS. Obesity—a critical issue in preventive cardiology: the Bogalusa Heart Study. *Prev Cardiol* 2005;**8**:234–41.
12. Urbina EM, Gidding SS, Bao W, Elkasabany A, Berenson GS. Association of fasting blood sugar level, insulin level, and obesity with left ventricular mass in healthy children and adolescents: the Bogalusa Heart Study. *Am Heart J* 1999;**138**:122–7.
13. Toemen L, Santos S, Roest AA et al. Body fat distribution, overweight, and cardiac structures in school-age children: a population-based cardiac magnetic resonance imaging study. *J Am Heart Assoc* 2020;**9**:e014933.
14. Banerjee R, Rial B, Holloway CJ, Lewandowski AJ, Robson MD, Osuchukwu C et al. Evidence of a direct effect of myocardial steatosis on lv hypertrophy and diastolic dysfunction in adult and adolescent obesity. *JACC Cardiovasc Imaging* 2015;**8**:1468–70.
15. Kooijman MN, Kruithof CJ, van Duijn CM, Duijts L, Franco OH, van IJendoorn MH et al. The Generation R Study: design and cohort update 2017. *Eur J Epidemiol* 2016;**31**:1243–64.
16. Gaillard R, Steegers EAP, Tiemeier H, Hofman A, Jaddoe VWW. Placental vascular dysfunction, fetal and childhood growth, and cardiovascular development: the generation R study. *Circulation* 2013;**128**:2202–10.
17. Haycock GB, Schwartz GJ, Wisotsky DH. Geometric method for measuring body surface area: a height-weight formula validated in infants, children, and adults. *J Pediatr* 1978;**93**:62–6.
18. Fredriks AM, van Buuren S, Burgmeijer RJF, Meulmeester JF, Beuker RJ, Brugman E et al. Continuing positive secular growth change in the Netherlands 1955–1997. *Pediatr Res* 2000;**47**:316–23.
19. Cole TJ, Bellizzi MC, Flegal KM, Dietz WH. Establishing a standard definition for child overweight and obesity worldwide: international survey. *BMJ* 2000;**320**:1240–3.
20. Lamata P, Niederer S, Nordsletten D, Barber DC, Roy I, Hose DR et al. An accurate, fast and robust method to generate patient-specific cubic Hermite meshes. *Med Image Anal* 2011;**15**:801–13.
21. Lamata P, Sinclair M, Kerfoot E et al. An automatic service for the personalization of ventricular cardiac meshes. *J R Soc Interface* 2014;**11**:20131023.
22. Vinnakota KC, Bassingthwaight JB. Myocardial density and composition: a basis for calculating intracellular metabolite concentrations. *Am J Physiol Heart Circ Physiol* 2004;**286**:1742–9.
23. Ryan T, Petrovic O, Dillon JC, Feigenbaum H, Conley MJ, Armstrong WF et al. An echocardiographic index for separation of right ventricular volume and pressure overload. *J Am Coll Cardiol* 1985;**5**:918–24.
24. Daniels SR, Meyer RA, Liang Y, Bove KE. Echocardiographically determined left ventricular mass index in normal children, adolescents and young adults. *J Am Coll Cardiol* 1988;**12**:703–8.
25. Henry WL, Gardin JM, Ware JH. Echocardiographic measurements in normal subjects from infancy to old age. *Circulation* 1980;**62**:1054–61.
26. Trieber FA, McCaffrey F, Pflieger K, Rauniker RA, Strong WB, Davis H et al. Determinants of left ventricular mass in normotensive children. *Am J Hypertens* 1993;**6**:505–13.
27. Verhaaren HA, Schieken RM, Mosteller M, Hewitt JK, Eaves LJ, Nance WE et al. Bivariate genetic analysis of left ventricular mass and weight in pubertal twins (the Medical College of Virginia Twin Study). *Am J Cardiol* 1991;**68**:661–8.
28. Medrano-Gracia P, Cowan BR, Ambale-Venkatesh B, Bluemke DA, Eng J, Finn JP et al. Left ventricular shape variation in asymptomatic populations: the multi-ethnic study of atherosclerosis. *J Cardiovasc Magn Reson* 2014;**16**:56.
29. van der Ven JPG, Sadighy Z, Valsangiacomo Buechel ER, Sarikouch S, Robbers-Visser D, Kellenberger CJ et al. Multicentre reference values for cardiac magnetic resonance imaging derived ventricular size and function for children aged 0–18 years. *Eur Heart J Cardiovasc Imaging* 2020;**21**:102–13.
30. Koopman LP, Mertens LL. Impact of childhood obesity on cardiac structure and function. *Curr Treat Options Cardiovasc Med* 2014;**16**:345.
31. Daniels SR, Kimball TR, Morrison JA, Khoury P, Witt S, Meyer RA et al. Effect of lean body mass, fat mass, blood pressure, and sexual maturation on left ventricular mass in children and adolescents: statistical, biological, and clinical significance. *Circulation* 1995;**92**:3249–54.
32. Mauger C, Gilbert K, Lee AM, Sanghvi MM, Aung N, Fung K et al. Right ventricular shape and function: cardiovascular magnetic resonance reference morphology and biventricular risk factor morphometrics in UK Biobank. *J Cardiovasc Magn Reson* 2019;**21**:1–13.
33. Ambale-Venkatesh B, Yoneyama K, Sharma RK, Ohyama Y, Wu CO, Burke GL et al. Left ventricular shape predicts different types of cardiovascular events in the general population. *Heart* 2017;**103**:499–507.
34. Heckbert SR, Post W, Pearson GDN, Arnett DK, Gomes AS, Jerosch-Herold M et al. Traditional cardiovascular risk factors in relation to left ventricular mass, volume, and systolic function by cardiac magnetic resonance imaging. The Multiethnic Study of Atherosclerosis. *J Am Coll Cardiol* 2006;**48**:2285–92.
35. Chan K, Mahmood M, Zacur E et al. Reappraising remodelling pattern of left ventricle in aortic stenosis: axis orientation as a unique signature of positive remodelling. In: *Heart*. BMJ; 2019. pA18.1–A18.
36. Heng MK, Janz RF, Jobin J. Estimation of regional stress in the left ventricular septum and free wall: an echocardiographic study suggesting a mechanism for asymmetric septal hypertrophy. *Am Heart J* 1985;**110**:84–90.
37. Florian A, Masci PG, De Buck S, Aquaro GD, Claus P, Todiere G et al. Geometric assessment of asymmetric septal hypertrophic cardiomyopathy by CMR. *JACC Cardiovasc Imaging* 2012;**5**:702–11.
38. Neeland JJ, Gupta S, Ayers CR, Turer AT, Rame JE, Das SR et al. Relation of regional fat distribution to left ventricular structure and function. *Circ Cardiovasc Imaging* 2013;**6**:800–7.
39. Gaasch WH, Zile MR. Left ventricular structural remodeling in health and disease: with special emphasis on volume, mass, and geometry. *J Am Coll Cardiol* 2011;**58**:1733–40.
40. Marchesseau S, Ho JXM, Totman JJ. Influence of the short-axis cine acquisition protocol on the cardiac function evaluation: a reproducibility study. *Eur J Radiol Open* 2016;**3**:60–6.
41. Medrano-Gracia P, Cowan BR, Bluemke DA, Finn JP, Kadish AH, Lee DC et al. Atlas-based analysis of cardiac shape and function: correction of regional shape bias due to imaging protocol for population studies. *J Cardiovasc Magn Reson* 2013;**15**:80.